

Original Article

Evaluation of the Sherlock 3CG Tip Confirmation System on peripherally inserted central catheter malposition rates

A. J. Johnston,¹ A. Holder,² S. M. Bishop,² T. C. See³ and C. T. Streater⁴

1 Consultant Intensivist, 2 Speciality Trainee, John Farman Intensive Care Unit, 3 Consultant Interventional Radiologist, Department of Radiology, 4 Specialist Nurse, Vascular Access Unit, Addenbrooke's Hospital, Cambridge University Hospitals NHS Foundation Trust, Cambridge, UK

Summary

Peripherally inserted central catheters are often positioned blindly in the central circulation, and this may result in high malposition rates, especially in critically ill patients. Recently, a new technology has been introduced (Sherlock 3CG Tip Positioning System) that uses an electro-magnetic system to guide positioning in the superior vena cava, and then intra-cavity ECG to guide positioning at the cavo-atrial junction. In this observational study, we investigated how the Sherlock 3CG Tip Positioning System would affect peripherally inserted central catheter malposition rates, defined using a post-insertion chest radiograph, in critically ill patients. A total of 239 catheters positioned using the Sherlock 3CG Tip Positioning System were analysed. When an adequate position was defined as low superior vena cava or cavo-atrial junction, 134 catheters (56.1%; 95% CI 50–62%) were malpositioned. When an adequate position was defined as mid/low superior vena cava, cavo-atrial junction or high right atrium (≤ 2 cm from cavo-atrial junction), 49 (20.5%; 95% CI 16–26%) catheters were malpositioned. These malposition rates are significantly lower than our own historical data, which used a 'blind' anthropometric technique to guide peripherally inserted central catheter insertion.

Correspondence to: A. Johnston

Email: andrew.johnston@addenbrookes.nhs.uk

Accepted: 26 May 2014

Introduction

Peripherally inserted central catheters (PICCs) are increasingly being used to provide access to the central venous circulation. They are frequently used for infusions that are irritant to the vascular endothelium, and are often left in position for several weeks or months; it is therefore vital that the tip of the PICC is in an adequate position within the central circulation.

Peripherally inserted central catheters are frequently positioned 'blindly' in the central circulation, with a post-insertion chest radiograph used to confirm the position of the catheter tip. This 'blind' method

commonly uses a combination of anthropometric measurements and operator experience to guide catheter length. We have previously shown that this method of catheter tip positioning may result in malposition rates of 42–76%, with a higher malposition rate in critically ill patients than in the general hospital population [1].

A number of techniques exist to reduce the incidence of catheter tip malposition, including X-ray fluoroscopy. However, X-ray fluoroscopy is an expensive resource, and impractical in critically ill patients. One technology that is better suited to bedside insertion is the use of intra-cavity ECG, in which the catheter is

inserted until the tip is positioned at the point of maximum p wave; this is thought to correspond anatomically to the cavo-atrial junction [2]. If the catheter tip is advanced further, the p wave becomes biphasic, which is thought to correspond to entry into the right atrium. This method relies on the ability to position the catheter tip 'blindly' in the superior vena cava, before advancing using the ECG to guide depth. One manufacturer has recently developed a system that combines intra-cavity ECG with an electro-magnetic positioning system (Sherlock 3CG Tip Confirmation System; Bard Access Systems, Salt Lake City, UT, USA), Fig. 1. The electro-magnetic positioning system consists of a magnet-tipped stylet that is inserted through the PICC and left level with the tip, and a sensor that is placed over the chest wall. The sensor, which is calibrated before insertion, contains an array of 3-axis magnetic sensor microchips, and provides magnetic field information that is used to triangulate the three-dimensional position and orientation of the stylet relative to the sensor. The electro-magnetic

positioning system assists with initial placement of the catheter tip in the superior vena cava, after which the ECG system can be used to guide the final position relative to the cavo-atrial junction.

In April 2013, we started using the Sherlock 3CG Tip Confirmation System to place PICCs in patients in the intensive care unit (ICU). This patient group was selected because we had previously seen a high catheter malposition rate. The primary outcome measure was the malposition rate of PICCs inserted in patients in the ICU using the Sherlock 3CG Tip Confirmation System.

As per our previous study, we used two definitions of correct tip position to define malposition rates. The first definition was siting of the tip in the low superior vena cava or cavo-atrial junction (based broadly on North American guidelines). The second definition was siting of the tip in the mid or low superior vena cava, at the cavo-atrial junction or in the high right atrium (based broadly on our own practice and European guidelines) [1].

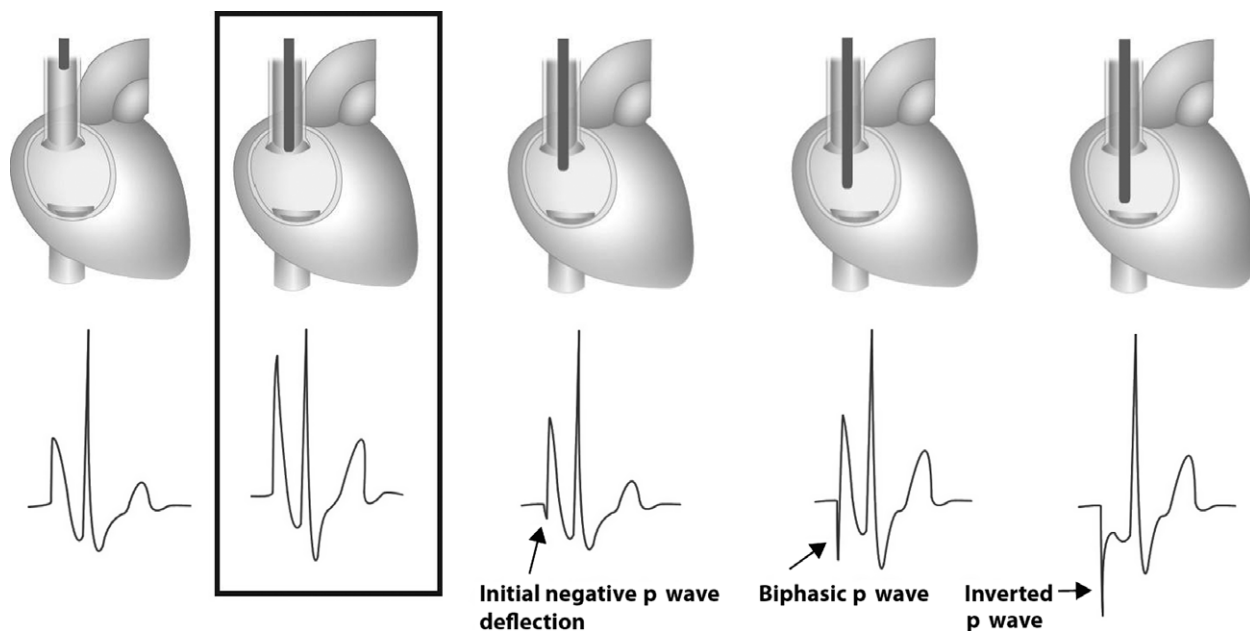


Figure 1 Schematic diagram showing how the intra-cavity ECG changes as the peripherally inserted central catheter (PICC) is inserted down the superior vena cava, through the cavo-atrial junction, and into the right atrium. As the PICC reaches the pericardial reflection, the p wave starts to become more peaked. The peaked p wave reaches its maximum height as the PICC reaches the cavo-Atrial junction. As the PICC enters the right atrium then the p wave becomes biphasic. In this study, the PICC was positioned at the point of maximum p wave (at the cavo-atrial junction). Image reproduced with permission of C. R. Bard, Inc.

Methods

This retrospective study was approved as a service evaluation by Cambridge University Hospitals NHS Foundation Trust's Research and Development Department. We collected data using the hospital's electronic vascular access database for adult patients who had a PICC, after obtaining permission from the hospital's Caldicott Guardian to use the data in a publication.

Specialist Nurses from the Trust Vascular Access Team (VAT) inserted all the PICCs. The VAT has been established in our hospital since 2006, and currently inserts over 2000 PICCs per year. There were no changes in VAT organisation, insertion techniques, equipment, or patient population during the period of evaluation, other than the introduction of the Sherlock 3CG Tip Confirmation System for PICC insertion in patients in the ICU.

The Y-shaped magnetic sensor and external ECG electrodes were placed on the patient's chest/abdomen (one electrode at the right shoulder and one electrode in the mid-axillary line below the umbilicus), before insertion (Fig. 2). We assessed the ECG to ensure that

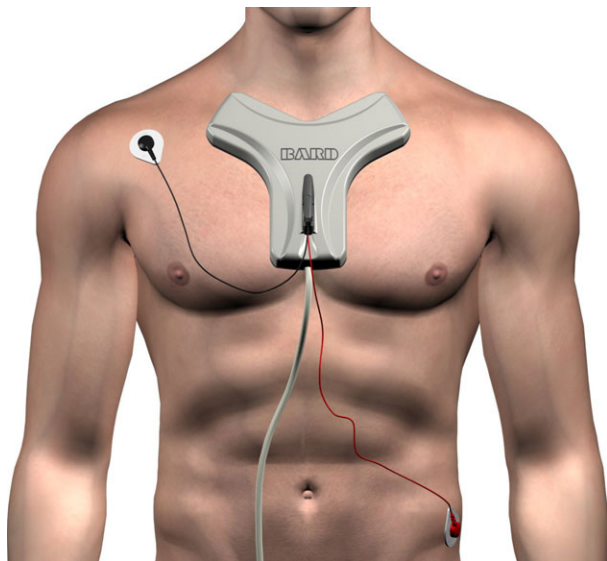


Figure 2 Positioning of the ECG electrodes (for external ECG monitoring) and the electro-magnetic positioning system (the Sherlock part of the Sherlock 3CG tip positioning system). The intra-cavity ECG is monitored via a magnet-tipped wire that is inserted through the peripherally inserted central catheter (not shown). Bard and Sherlock 3CG are trademarks and/or registered trademarks of C. R. Bard, Inc. or an affiliate (Image reproduced with permission of C. R. Bard, Inc.).

there was a distinguishable p wave. The catheter used for all patients in this group was a Bard Solo double-lumen 5-Fr peripherally inserted central catheter (Bard Access Systems). An ultrasound scan of the upper arm veins was performed to determine a suitable insertion site. As per the usual practice in our institution, the diameters of the upper arm veins were not formally assessed, nor were the axillary/subclavian veins formally assessed with ultrasound. In the majority of cases, a basilic vein insertion site was chosen. The PICC was cut to the approximate anticipated length before insertion, as per the manufacturer's instructions, using the following anthropometric measurements: insertion site to axillary crease distance + axillary crease to sternal notch distance + 13 cm. This included some leeway, and usually resulted in a short length of catheter external to the insertion site. The catheter was subsequently prepared such that the pre-loaded magnetic-tipped stylet was left level with the tip of the catheter. The catheter was inserted into one of the upper arm veins using an ultrasound-guided out-of-plane Seldinger micropuncture/split-sheath, with the arm abducted to approximately 90°. The decision for left- or right-sided insertion was operator-dependent.

The PICC was advanced into the central circulation using the magnet tracking display of the Sherlock system to guide a position in the superior vena cava. The ECG system was then used until the p wave on the display was at its maximum height and the catheter was left at this point. The intravascular ECG signal is a voltage measurement between the tip of the catheter and the left-leg electrode on the patient. ECG positioning was not used in patients who were not in sinus rhythm, and these patients were excluded from subsequent analysis.

All ICU PICC insertions were performed at the bed space, as per standard hospital practice. Details of the procedure were electronically documented on the Trust's vascular access database. Routine portable chest radiographs were obtained immediately after PICC insertion to assess the catheter position, and were reviewed by the referring ICU team. If the PICC needed to be withdrawn, this was done by the ICU team. If, however, it needed re-siting, the VAT was asked to do this.

We collected data on the first 250 adult ICU (general adult ICU or neurosciences critical care unit) PICC insertions, starting on the date that the Sherlock 3CG Tip Confirmation System was first introduced in our institution (8 April 2013). This number was chosen to provide a fair comparison with our historical data [1]. For each ICU PICC insertion, the following data were collected from the hospital's vascular access database: hospital number; insertion date; insertion side; insertion length; and any problems encountered during the insertion. The patient's hospital number and the date of insertion were cross-referenced to the hospital's Picture Archiving and Communications System. We reviewed the chest radiograph following PICC insertion to determine the catheter tip position according to the definitions in Table 1. Catheter tip position was defined according to a method that we have previously published [1]. All chest radiographs were independently reviewed by two of the authors (AJJ, AH).

To determine malposition rates, we defined adequate tip position in two different ways, and calculated

the malposition rates for each definition. One definition was catheter tip in the mid/low superior vena cava, cavo-atrial junction or high right atrium (considered by the authors to be an ideal final position). The second definition was catheter tip in the low superior vena cava or at the cavo-atrial junction.

When the catheter tip was positioned in the right atrium, the distance between the cavo-atrial junction and the tip was determined. High right atrium was defined as < 2 cm from the cavo-atrial junction.

The number of PICCs with a tip situated at each of our defined positions was recorded. We directly calculated the number of malpositioned peripherally inserted central catheter tips (by each of our two definitions for tip position adequacy) and a corresponding malposition rate with 95% confidence interval CI (by the Wilson procedure).

All statistical tests were performed using the R statistical package v2.13.1 (The R Foundation for Statistical Computing, Vienna, Austria) and two-tailed *p* values < 0.05 were considered to be statistically significant.

Table 1 Chest radiograph definitions for peripherally inserted central catheter (PICC) tip position.

PICC tip position	Chest radiograph interpretation of PICC tip position
Axillary vein*	Tip positioned between the lateral borders of the rib cage and the lateral border of the first rib
Internal jugular vein*	Tip positioned above the superior border of the clavicle
Subclavian vein*	Tip position medial to the axillary vein, but above the inferior border of the medial end of the clavicle
Brachiocephalic vein*	Tip position below the inferior border of the medial end of the clavicle, but above the superior vena cava
High superior vena cava	Tip position within one posterior rib height distance (fifth, sixth or seventh rib measured at the mid-clavicular line) of the superior border of the origin of the right main bronchus down to the right main bronchus. In addition, for left-sided catheters, the tip had to have crossed the right border of the trachea
Mid superior vena cava	Tip position superimposed over the right main bronchus
Low superior vena cava	Tip position below the right main bronchus, but above the cavo-atrial junction
Cavo-atrial junction	The cavo-atrial junction was defined as being in a position two vertebral body units (one vertebral body unit equal to vertebral body plus vertebral disc) below the lower border of the carina
Right atrium	Tip positioned between the cavo-atrial junction and either the right ventricle or the inferior vena cava. When the PICC tip was positioned in the right atrium, the distance between the cavo-atrial junction and the tip was determined
High right atrium	High right atrium was defined as a position within the right atrium and less than or equal to 2 cm from the cavo-atrial junction
Right ventricle	Tip position past the cavo-atrial junction and crossing the midline
Inferior vena cava	Tip position past the cavo-atrial junction and below the diaphragm
Other (e.g. coiled)	Unable to determine tip position due to catheter coiling or other abnormalities

*Ipsilateral or contralateral. Ipsilateral = peripherally inserted central catheter tip situated in a vessel on ipsilateral side to catheter insertion. Contralateral = peripherally inserted central catheter tip situated in a vessel on contralateral side to catheter insertion.

Results

A total of 250 PICCs were inserted using the Sherlock 3CG tip positioning system. Out of these, 11 were excluded from further analysis for the following reasons: failed insertions (2); no chest radiograph after procedure (2); not possible to determine tip position on chest radiograph (2); unable to interpret ECG criteria (4); and catheter not long enough for adequate insertion length (1). We therefore analysed 239 placements. Eighty-five PICCs were inserted from the right side (35.6%) and 154 from the left (64.4%). The mean (SD) length of insertion was 43.6 (3.91) cm for right-sided insertions and 46.4 (3.7) cm for left-sided insertions.

The PICC tip positions for the Sherlock 3CG insertions are shown in Table 2. For Sherlock 3CG PICCs positioned in the right atrium, the mean (SD) distance from the cavo-atrial junction was 2.0 (1.1) cm.

Table 2 Peripherally inserted central catheter tip position on plain chest radiograph for catheters inserted using the Sherlock 3CG Tip Confirmation System (failed insertions have been excluded). Values are number (proportion).

Tip position	Sherlock 3CG positioning (n = 239)
Axillary vein (contralateral)	0
Axillary vein (ipsilateral)	0
Internal jugular vein (contralateral)	0
Internal jugular vein (ipsilateral)	0
Subclavian vein (contralateral)	0
Subclavian vein (ipsilateral)	0
Brachiocephalic vein (contralateral)	0
Brachiocephalic vein (ipsilateral)	1 (0.4%)
High superior vena cava	7 (2.9%)
Mid superior vena cava	22 (9.2%)
Low superior vena cava	58 (24.2%)
Cavo-atrial junction	47 (19.6%)
High right atrium (upper 2 cm)	63 (26.3%)
Low right atrium (below 2 cm)	39 (16.3%)
Right ventricle	0
Inferior vena cava	1 (0.4%)
Other (e.g. coiled)	1 (0.4%)

[Correction added on 15 August 2014, after first online publication: 10 July 2014: In Table 2, Right atrium (total) was changed to High right atrium (upper 2 cm). High right atrium (upper 2 cm) was changed to Low right atrium (below 2 cm)].

Table 3 Incorrectly/malpositioned peripherally inserted central catheters for two different definitions of adequate catheter tip. Values are number (proportion (95% CI)). High right atrium is defined as within 2 cm of the cavo-atrial junction.

Definition of adequate tip position	Sherlock 3CG positioning malpositioned catheters n = 239
Low superior vena cava/cavo-atrial junction	134 (56.1% (50–62%))
Mid superior vena cava/low superior vena cava/cavo-atrial junction/high right atrium	49 (20.5 (16–26%))

Catheter malposition rates are found in Table 3. To study this effect further as a post-hoc analysis we varied the definition of high right atrium from 0 to 1 cm to 0 to 5+ cm and studied its effect on the malposition rate (Table 4). Using Sherlock 3CG, the malposition rate fell to below 10% when high right atrium was defined as 0–4 cm from the cavo-atrial junction.

Peripherally inserted central catheters that are inserted too far are relatively easy to pull back, whereas catheters that are not inserted far enough or are in an aberrant position are difficult to insert further. To explore this issue further, we looked at the proportion of PICCs that were in ‘too far’ (beyond high right atrium) and the proportion of PICCs that were not in ‘far enough’ or were in an aberrant position (high superior vena cava or above). If a catheter was misplaced with the Sherlock 3CG, it was significantly more likely to have been inserted too far as opposed to left short (too far vs too short: 40/239 vs 9/239, $p < 0.0001$). [Correction added on 15 August 2014, after first online publication: 10 July 2014: values in the last sentence of the Results section were changed from ‘25/239 vs 8/239, $p = 0.0033$ ’ to ‘40/239 vs 9/239, $p < 0.0001$ ’].

Discussion

The malposition rate using the Sherlock 3CG (21%) is consistent with other data reported in the literature. In one Italian study, the authors performed 1444 catheter insertions using intra-cavity ECG monitoring, with an

Table 4 The effect of different definitions of high right atrium on peripherally inserted central catheter malposition rates. Values are number (proportion (95% CI)).

Definition of adequate tip position	Sherlock 3CG positioning malpositioned catheters n = 239
Mid superior vena cava/low superior vena cava/cavo-atrial junction/high right atrium (0–1 cm)	94 (39.3% (33–46%))
Mid superior vena cava/low superior vena cava/cavo-atrial junction/high right atrium (0–2 cm)	49 (20.5% (16–26%))
Mid superior vena cava/low superior vena cava/cavo-atrial junction/high right atrium (0–3 cm)	30 (12.6% (8.9–17%))
Mid superior vena cava/low superior vena cava/cavo-atrial junction/high right atrium (0–4 cm)	15 (6.3% (3.8–10%))
Mid superior vena cava/low superior vena cava/cavo-atrial junction/high right atrium (0–5 cm)	12 (5% (2.9–8.6%))
Mid superior vena cava/low superior vena cava/cavo-atrial junction/any right atrium	10 (4.2% (2.3–7.5%))

acceptable position on post-procedural CXR defined as in the lower third of the superior vena cava, cavo-atrial junction and upper right atrium. They demonstrated a malposition rate of 17% [3]. Another recent study from America reported a malposition rate of only 2.3%, but with a higher exclusion rate and a more liberal definition on adequate placement that included any position in the brachiocephalic veins, superior vena cava and right atrium [4]. In addition, the authors did not describe how chest radiographs were interpreted. We believe that our higher malposition rate is related to a more complex patient group that is known to have a higher malposition rate, and also reflects a different way of defining and interpreting malposition. We have previously explored some of the methodological issues surrounding the difficulty in defining malposition rate on a post-insertion chest radiograph [1]. These issues make it difficult to compare malposition rates between different studies and institutions.

Compared with the malposition rates seen in our previously published cohort, the Sherlock 3CG system appeared to have a favourable effect on PICC malposition rates [1]. Our previous series was in a comparable series of ICU patients, but used an anthropometric 'blind' technique for positioning the PICC. In this earlier series, we found a malposition rate of 76% when an adequate position was defined as low superior vena cava or cavo-atrial junction, and a malposition rate of 50.8% when an adequate position was defined as mid/low superior vena cava. Cavo-atrial junction or high right atrium. Despite the limitations of the comparison, both of these differences are significant

($p < 0.0001$, two-tailed chi-squared test with Yate's correction). Both studies were performed in the same hospital, in the same patient group, by the same members of staff and without any obvious changes in practice or patient profile other than the introduction of Sherlock 3CG technology, and we therefore believe there may be value in making limited comparisons with our previous case series.

In our current study, we analysed the positions of PICCs that had been inserted into patients in the ICU to provide short- to medium-term access to the central venous circulation. These catheters were often going to be left in situ for some weeks or even months, and were frequently going to be used for infusions that are vasoactive (e.g. noradrenaline) or are irritant to vascular endothelium (e.g. parenteral nutrition). In addition, the PICC was frequently used to take blood samples for central venous blood gases analysis. For these reasons, we sought a final tip position in the central venous circulation, where blood samples would accurately reflect central venous gases, and where irritant drugs would be diluted as quickly as possible by a high blood flow. The part of the central venous circulation that fulfils these criteria is within the superior vena cava, at the junction between the superior vena cava and the right atrium or within the right atrium itself. The use of Sherlock 3CG almost completely removed the incidence of catheter tips positioned outside this area (only one catheter (0.4%) was outside this position). This was a dramatic improvement when compared with our previous case series, in which 21% of catheters were outside this position [1].

The Sherlock 3CG system also appeared to have a favourable effect on the type of misplacement that occurred. If a catheter was misplaced when using the Sherlock 3CG, it was significantly more likely to be too far in as opposed to too short, simply requiring withdrawal to achieve an adequate position.

We believe that both the electro-magnetic guidance and the ECG positioning components contribute to the improved malposition rate – the electro-magnetic system for positioning at or near the superior vena cava, and the ECG for positioning at an appropriate level within the superior vena cava. Other technologies such as ultrasound have also been shown to reduce the incidence of aberrant position. In one study, neck ultrasound during the placement of PICCs in the ICU reduced the incidence of ipsilateral internal jugular vein placement from 7.9% to 0.7% [5]. However, ultrasound is not likely to help with brachiocephalic malpositions, nor is it likely to reduce the rate of high superior vena cava positions, which we do not believe to be an ideal tip position.

The use of Sherlock 3CG technology to position PICCs raises a number of important issues. The first of these is that the 3CG technology specifically targets the cavo-atrial junction; however, our data show that only 20% of catheters are actually positioned at this location. Even when the more liberal definition of low superior vena cava/cavo-atrial junction is used, only 56% of catheter tips are located at this position. There are a number of reasons why this might be. In a research setting, the appearance of a maximum p wave, and then a biphasic p wave, does appear to have a good relationship with the transition between the superior vena cava and the right atrium on transoesophageal echocardiogram [2]. However, in reality, it is sometimes difficult to determine exactly when the point of maximum p wave occurs, or when the biphasic p wave appears; this is especially true of the ICU population, where there is often considerable ECG artefact. Furthermore, it is incorrect to assume that the position attained at the time of insertion is static. The 3CG technology may target the cavo-atrial junction; however, the tip position is not static, moving according to factors such as patient position [6], respiration [7] and arm movement [8]. Arm movement is especially relevant with PICCs, with the catheter tip mov-

ing up to 53 mm caudally when the arm is moved from an abducted position to an adducted position [8]. This is exactly the type of movement that occurs between the catheter's being inserted (with the arm abducted to approximately 90°) and a post-procedural chest radiograph (taken with the arm in an adducted position).

The second issue is the use of chest radiographs to define post-insertion malposition rates. We have previously described a way to define the anatomical location of a catheter tip, in terms of central venous circulation, on a plain chest radiograph [1]. This method uses bony and airway landmarks, which can be seen on a chest radiograph, to define the position of structures such as the brachiocephalic veins and the superior vena cava that cannot be seen on a chest radiograph. In addition, we developed methods to define the transition between different regions of the superior vena cava such as high, mid and low superior cava – distinctions that are commonly made in the literature, but that are often poorly defined. Whilst we believe this method provides a valid and reproducible anatomical description of tip position, we do recognise that there is considerable inter-individual variability in anatomy and that no system will provide an exact anatomical location. The fact that many of the catheter tips appeared not to be positioned at the cavo-atrial junction could be explained by the inability to view this location on a plain chest radiograph. However, two vertebral body units below the carina has previously been described as a good landmark to define the cavo-atrial junction [9], and we do not believe that the wide variability that we saw on post-insertion chest radiographs can be explained solely by the inability to define the junction on a chest radiograph. The validity of our chest radiograph interpretation was further improved by having two of the authors independently assess all the chest radiographs with input from a consultant radiologist when required. This is a technique we have employed to good effect in our previous work.

The third issue concerns what constitutes malposition. In our opinion, an ideal tip position is in the mid to low superior vena cava, at the cavo-atrial junction, or in the high right atrium. This definition is consistent with European guidelines [10] and those of other

authors [3, 11], but not with American guidelines, where the low superior vena cava or cavo-atrial junction is recommended [12–14]. We have used these two definitions to define our malposition rates. We believe that a high superior vena cava position is inadequate for several reasons. Firstly, previous studies have demonstrated an increased risk of catheter-related central venous thrombosis, notably in oncology patients [15]. Secondly, a high superior vena cava position creates an angle between the wall of the superior vena cava and the catheter tip [16], and in-vitro studies suggest that this may increase the risk of vessel erosion [17]. Thirdly, in our hospital practice, catheters in this position are found to malfunction more frequently.

There is controversy over whether the right atrium is an appropriate place to site central venous catheters. The commonest argument for avoiding this location is fear of erosion and cardiac tamponade; however, the same risk exists with erosion through any part of the superior vena cava below the pericardial reflection. To avoid this complication, catheters would have to be positioned at or above the level of the carina [16, 18, 19]. Furthermore, although the exact incidence of catheter-associated pericardial tamponade is unknown, it is thought to be an extremely rare event, with only a handful of cases reported in the world literature [20]. Many guidelines now accept the high right atrium as an adequate tip position [10, 21]. Although many authors speak about high right atrium, there is no accepted definition of what 'high' constitutes. In this study, we have defined high right atrium as within 2 cm of the cavo-atrial junction; we accept that this is a purely artificial definition. More conservative definitions of what constitutes an adequate right atrial position would obviously increase malposition rates, and the converse would be true if definitions were to be made more liberal. The malposition rate fell to a clinically acceptable value of less than 10% when a definition of high right atrium was within 0–4 cm of the cavo-atrial junction. If any right atrial position was considered acceptable, then our malposition rate using Sherlock 3CG would fall to just over 4%.

The final issue is whether it is still necessary to obtain a chest radiograph after a straightforward peripherally inserted central catheter insertion using

Sherlock 3CG technology. The answer to this depends on one's attitude to acceptable final position. If a low superior vena cava/cavo-atrial junction position is sought, as per some North American guidelines, then our data suggest that Sherlock 3CG positioning alone is inadequate. If, however, more liberal definitions of adequate position are used, then Sherlock 3CG positioning alone is sufficient. This is a question that the vascular access community needs to address.

We have demonstrated that the use of Sherlock 3CG positioning technology gives a favourable malposition rate compared with the published literature and our own historical cohort. This was a pragmatic study in a difficult and complex patient population, where the rate of malposition is known to be high. The study has several limitations, the most important of which is that it is observational rather than a randomised controlled study, and therefore only limited comparisons can be made with other data, including with our own previously published data. The results of this study could certainly be used to inform the design of future randomised controlled trials.

Manipulation of the peripherally inserted central catheter after Sherlock 3CG positioning may further reduce the malposition rate. In particular, it is our current practice to insert the PICC with the arm in abduction and then perform a chest radiograph with the arms adducted. This may explain why some of the Sherlock 3CG catheters are in 'too far'. Placing the arm into an adducted position before the final positioning of the PICC using the intra-cavity ECG may reduce malposition rates, and should be studied.

A reduction in the number of catheters that need to be resited, and the avoidance of routine post-insertion radiographs, may make this a cost-effective technique, and a detailed cost/benefit analysis should form the basis of future work. This technology also has the potential to be used for other types of central venous catheters; however, any benefit from its use may depend on the type of catheter and the vein used.

Our data suggest that the use of the Sherlock 3CG system reduces the number of catheters that have to be repositioned when compared with a previous case series; a randomised controlled trial would be needed to confirm this.

Competing interests

Two of the authors (AJJ and CTS) have received honoraria in the past from Bard Access Systems. No external funding declared. This study and the necessary equipment and consumables were funded entirely by institutional sources.

References

1. Johnston AJ, Bishop SM, Martin L, See TC, Streater CT. Defining peripherally inserted central catheter tip position and an evaluation of insertions in one unit. *Anaesthesia* 2013; **68**: 484–91.
2. Jeon Y, Ryu HG, Yoon SZ, Kim JH, Bahk JH. Transesophageal echocardiographic evaluation of ECG-guided central venous catheter placement. *Canadian Journal of Anesthesia* 2006; **53**: 978–83.
3. Pittiruti M, Bertollo D, Briglia E, Buononato M, Capozzoli G, De Simone L, et al. The intracavitary ECG method for positioning the tip of central venous catheters: results of an Italian multi-center study. *Journal of Vascular Access* 2012; **13**: 357–65.
4. Lelkes V, Kumar A, Shukla PA, Contractor S, Rutan T. Analysis of the Sherlock II tip location system for inserting peripherally inserted central venous catheters. *Clinical Imaging* 2013; **37**: 917–21.
5. Schweickert WD, Herlitz J, Pohlman AS, Gehlbach BK, Hall JB, Kress JP, et al. A randomized, controlled trial evaluating post-insertion neck ultrasound in peripherally inserted central catheter procedures. *Critical Care Medicine* 2009; **37**: 1217–21.
6. Kowalski CM, Kaufman JA, Rivitz SM, Geller SC, Waltman AC. Migration of central venous catheters: implications for initial catheter tip positioning. *Journal of Vascular and Interventional Radiology* 1997; **8**: 443–7.
7. Donnelly ED, Parikh PJ, Lu W, Zhao T, Lechleiter K, Nystrom M, et al. Assessment of intrafraction mediastinal and hilar lymph node movement and comparison to lung tumor motion using four-dimensional CT. *International Journal of Radiation Oncology Biology Physics* 2007; **69**: 580–8.
8. Forauer AR, Alonzo M. Change in peripherally inserted central catheter tip position with abduction and adduction of the upper extremity. *Journal of Vascular and Interventional Radiology* 2000; **11**: 1315–8.
9. Baskin KM, Jimenez RM, Cahill AM, Jawad AF, Towbin RB. Cavoatrial junction and central venous anatomy: implications for central venous access tip position. *Journal of Vascular and Interventional Radiology* 2008; **19**: 359–65.
10. Pittiruti M, Hamilton H, Biffi R, MacFie J, Pertkiewicz M. ESPEN Guidelines on Parenteral Nutrition: central venous catheters (access, care, diagnosis and therapy of complications). *Clinical Nutrition* 2009; **28**: 365–77.
11. Fletcher SJ, Bodenham AR. Safe placement of central venous catheters: where should the tip of the catheter lie? *British Journal of Anaesthesia* 2000; **85**: 188–91.
12. NAVAN Position Paper: tip location of peripherally inserted central catheters. *Journal of Vascular Access Devices* 1998; **3**: 1–4.
13. Infusion Nurses Society. Infusion nursing standards of practice. *Journal of Infusion Nursing* 2006; **29**(1 Suppl): S1–92.
14. Funaki B. Central venous access: a primer for the diagnostic radiologist. *American Journal of Roentgenology* 2002; **179**: 309–18.
15. Verso M, Agnelli G, Kamphuisen PW, Ageno W, Bazzan M, Lazzaro A, et al. Risk factors for upper limb deep vein thrombosis associated with the use of central vein catheter in cancer patients. *Internal and Emergency Medicine* 2008; **3**: 117–22.
16. Stonelake PA, Bodenham AR. The carina as a radiological landmark for central venous catheter tip position. *British Journal of Anaesthesia* 2006; **96**: 335–40.
17. Gravenstein N, Blackshear RH. In vitro evaluation of relative perforating potential of central venous catheters: comparison of materials, selected models, number of lumens, and angles of incidence to simulated membrane. *Journal of Clinical Monitoring* 1991; **7**: 1–6.
18. Schuster M, Nave H, Piepenbrock S, Pabst R, Panning B. The carina as a landmark in central venous catheter placement. *British Journal of Anaesthesia* 2000; **85**: 192–4.
19. Albrecht K, Nave H, Breitmeier D, Panning B, Troger HD. Applied anatomy of the superior vena cava—the carina as a landmark to guide central venous catheter placement. *British Journal of Anaesthesia* 2004; **92**: 75–7.
20. Orme RM, McSwiney MM, Chamberlain-Webber RF. Fatal cardiac tamponade as a result of a peripherally inserted central venous catheter: a case report and review of the literature. *British Journal of Anaesthesia* 2007; **99**: 384–8.
21. Bishop L, Dougherty L, Bodenham A, Mansi J, Crowe P, Kibbler C, et al. Guidelines on the insertion and management of central venous access devices in adults. *International Journal of Laboratory Hematology* 2007; **29**: 261–78.