

Clinical impact of the Sherlock 3CG[®] Tip Confirmation System for peripherally inserted central catheters

Journal of International Medical Research
0(0) 1–7

© The Author(s) 2018

Article reuse guidelines:

sagepub.com/journals-permissions

DOI: 10.1177/0300060518793802

journals.sagepub.com/home/imr

Tomomi Yamagishi , Hirokazu Ashida,
Takao Igarashi, Yo Matsui, Yosuke Nozawa,
Takahiro Higuchi and Hiroya Ojiri

Abstract

Objective: This study was performed to evaluate the technical success rate and catheter tip malposition rate of peripherally inserted central catheter (PICC) placement using the Sherlock 3CG[®] Tip Confirmation System (TCS).

Methods: In total, 114 patients who underwent PICC insertion via the Sherlock 3CG[®] TCS from October 2017 to February 2018 were retrospectively evaluated. The primary endpoints were the technical success rate, malposition rate, and mean procedure time. The secondary endpoints were the sex-related difference in the malposition rate, radiologist's experience level, and side of insertion. Technical success was defined as procedure completion using only the Sherlock 3CG[®] TCS without a guidewire or fluoroscopy guidance. In accordance with the North American guidelines, an adequate position was defined as the lower third of the superior vena cava and the cavoatrial junction.

Results: The technical success rate was 97% (111/114). The malposition rate was 16% (18/111), and four catheters were repositioned. There were no significant differences in the malposition rate between the sexes, radiologist's level of experience, or side of insertion.

Conclusions: PICC placement using the Sherlock 3CG[®] TCS yielded a high technical success rate and low catheter tip malposition rate regardless of the radiologist's level of experience or side of insertion.

Department of Radiology, The Jikei University School of
Medicine, Tokyo, Japan

Corresponding author:

Tomomi Yamagishi, Department of Radiology, The Jikei
University School of Medicine, 3-19-18 Nishi Shimbashi,
Minato-ku, Tokyo 105-8471, Japan.
Email: yamagishi@jikei.ac.jp



Keywords

Sherlock 3CG[®] TCS, catheter tip malposition, peripherally inserted central catheter, technical success rate, cavoatrial junction, chest radiograph

Date received: 8 May 2018; accepted: 19 July 2018

Introduction

A peripherally inserted central catheter (PICC) is a specific type of venous catheter. Normally, a PICC is inserted via a cephalic or basilic vein of the upper arm under ultrasonographic guidance, and the catheter tip is positioned at the superior vena cava (SVC) through the subclavian and brachiocephalic veins. The advantage of PICCs over centrally inserted venous catheters is the reduction in the risk of procedure-related complications such as a pneumothorax, hemothorax, or life-threatening hemorrhage. Catheter tip malposition is the most frequent problem encountered in PICC insertion because the procedure is blindly performed without fluoroscopic guidance.¹⁻⁵ Catheter tip malposition can trigger venous thrombosis or cardiac tamponade.⁶⁻¹⁰

The Sherlock 3CG[®] Tip Confirmation System (TCS) (Bard Access Systems, Salt Lake City, UT, USA) is composed of an external magnetic sensor at the catheter tip and an intracavity electrocardiography guidance system (IC-ECG). The Sherlock 3CG[®] TCS enables advancement of the catheter tip under the magnetic sensor's guidance system, which graphically shows the position of the catheter tip on a bedside monitor. When the catheter tip is located near the cavoatrial junction (CAJ), the p-waves of the IC-ECG gradually become higher, reaching a maximum at the CAJ. With these two guidance systems, the catheter tip can be advanced to the CAJ without using fluoroscopy. In a previous study, the

malposition rate among patients in the intensive care unit (ICU) who had undergone PICC insertion using the Sherlock 3CG[®] TCS was 56.1%.¹¹ However, to the best of our knowledge, no reports in the literature have addressed the clinical impact of PICC insertion using the Sherlock 3CG[®] TCS in normal (non-ICU) patients under a precise definition of adequate positioning evaluated by chest radiography. In this retrospective study, we evaluated the technical success rate and catheter tip malposition rate of PICC insertion using the Sherlock 3CG[®] TCS in normal (non-ICU) patients.

Materials and methods

The study was approved by our institutional review board, and the requirement to obtain informed consent from the patients was waived [approval number 29-363 (8979)]. The Sherlock 3CG[®] TCS was introduced in Japan in October 2017. Since then, we have been using the system for normally (non-ICU) hospitalized patients.

Consecutive patients who underwent procedures using PICCs in our radiology department from October 2017 to February 2018 were assessed for eligibility. We excluded patients with atrial fibrillation, those who had undergone pacemaker implantation, and those for whom the Sherlock 3CG[®] TCS catheter was unavailable. Five interventional radiologists with 1, 1, 6, 10, and 16 years of experience, respectively, conducted all procedures.

The radiologists were divided into two groups: the “beginner” group of first-year radiologists and the “skilled” group. The double-lumen Power PICC (Bard Access Systems) was used for all patients. The Y-shaped magnetic sensing device was placed in the anterior chest wall, and the ECG electrodes were placed on the right shoulder and left flank. The puncture point was confirmed using ultrasound. The choice of the right or left arm was based on the patient’s request to the greatest extent possible. The preferred puncture vein was the basilic vein. An alternative target was the deep brachial vein; the cephalic vein was avoided because the inflow angle into the axial vein was too sharp to advance the catheter. From the puncture point, the approximate extracorporeal distance was measured through the axilla, medial head of the right clavicle, and third intercostal space to adjust the length of the PICC. The PICCs were cut according to this measured distance. A magnetic-tipped stylet was left at the level of the catheter tip. The PICCs were inserted from a 5-Fr sheath that was introduced using Seldinger’s technique under ultrasound guidance via a 21-G puncture needle and a 0.018-inch guidewire. The PICCs were advanced into the SVC using the magnetic tracking display of the Sherlock system. The ECG system was then used. The catheter tip was advanced to the point at which the p-wave on the display monitor reached maximum height immediately before appearing as a negative wave. A chest radiograph was then obtained with the patient in the supine position on the table at maximum height and with the detector close to the patient’s chest. The radiograph was obtained with patient’s arm in adduction during deep inspiration. All procedures were performed in the interventional radiology room.

The primary outcomes were the technical success rate, malposition rate, and mean

procedure time. We defined technical success as positioning of the catheter tip at the CAJ point using only the Sherlock 3CG[®] TCS. Technical failure was defined as the need to advance the catheter tip using a guidewire or fluoroscopy guidance in addition to the Sherlock 3CG[®] TCS. Analysis of the malposition rate included cases in which the catheter was successfully inserted ($n = 111$).

An adequate catheter tip position was defined as the lower one-third of the SVC or CAJ according to the North American guidelines. Following previous reports in the literature,^{5,11} we defined positioning at the low SVC as localization of the tip below the right main bronchus, above the CAJ. Positioning at the CAJ was defined as localization of the tip within 2.4 vertebral body units (VBUs) from the tracheal carina on the chest radiograph obtained immediately after PICC insertion.¹² One VBU included one vertebral body and its disc. We calculated the procedure time as the time from opening the PICC kit until confirmation of the catheter tip position by a chest radiograph from routine clinical records.

The secondary outcomes were the sex-related difference in the malposition rate, the radiologist’s experience level (beginner or skilled), and the side of insertion. We used Fisher’s exact test to compare the malposition rates between the groups. The threshold for significance was $p < 0.05$. All statistical analyses were conducted using Ekuseru Toukei 2015 (SSRI, Tokyo, Japan).

Results

Of 140 consecutive patients who underwent procedures using PICCs, 114 patients (73 male and 41 female) were enrolled in the present study. The flow diagram for the patient selection process is shown in Figure 1. The patients’ demographics are listed in Table 1. There were no adverse

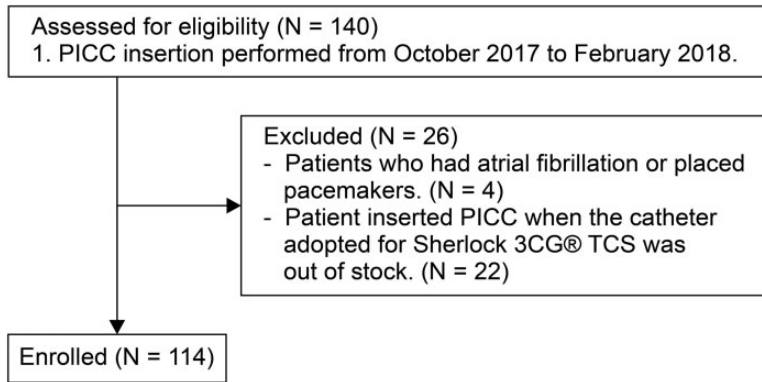


Figure 1. Flow diagram of the patient selection process.

PICC, peripherally inserted central catheter; TCS, Tip Confirmation System

Table 1. Patient demographics (N = 114)

Male sex	73 (64)
Left arm access site	59 (52)
Group S*	87 (76)

Data are presented as n (%)

*"Skilled" group

events (including life-threatening complications) during the procedures.

The overall technical success rate was 97.3% (111/114). Three cases of technical failure were attributable to the following: inability to interpret the magnetic guidance, thus requiring fluoroscopy (one case), and inability to extend the catheter forward through the subclavian vein, thus requiring a guidewire (two cases). The malposition rate was 16.2% (18/111). Among these 18 cases, 1 occurred at the upper SVC, 6 at the middle SVC, and 11 at the right atrium. The mean distance inside the right atrium was 19 mm from the CAJ. After identification of the malpositioned cases, four had an adequately repositioned catheter tip as shown by the chest radiograph. One upper SVC case was extended further, and three deep right atrium cases were retracted to the CAJ. In these three cases, the distance

Table 2. Results for malposition rate (N = 111)

	Malposition (n = 18)	Adequate position (n = 93)	p value
Difference between sexes			0.056
Male	8	65	
Female	10	28	
Difference between sides			0.44
Right	7	47	
Left	11	46	
Difference between experience level			0.77
Beginner group	5	22	
Skilled group	13	71	

inside the right atrium was 30, 38, and 45 mm, respectively. The other 14 cases could not be repositioned because they were in an adequate position according to the European guidelines (from the middle SVC to the high right atrium). We observed a slight difference in the malposition rate between the male and female patients (Table 2), but the difference was not statistically significant. There were no differences in the malposition rates in terms of the side of insertion or radiologist's experience level

(Table 2). The mean procedure length was 23.59 ± 6.56 minutes. The beginner group needed significantly more time than the skilled group (29.92 vs. 22.34 minutes, respectively; $p = 0.00024$).

Discussion

In this study, we investigated the technical success rate and malposition rate of PICC insertions using the Sherlock 3CG[®] TCS in normally hospitalized patients. The procedure yielded a high technical success rate (97.3%) and a low malposition rate (16.2%).

A previous retrospective study of 250 ICU patients who underwent PICC insertion with the Sherlock 3CG[®] TCS yielded 2 failed insertions and 1 case of a catheter that was too short for adequate insertion.¹¹ A recent randomized controlled trial showed that the technical success rates for the IC-ECG and blind methods were 89.2% and 77.4%, respectively.² Our high technical success rate was in accordance with those from previous studies. The success of PICC insertion using the Sherlock 3CG[®] TCS is related to the low technical failure rate regardless of the patient's condition.

There are two major sets of guidelines concerning the catheter tip position: the North American and European guidelines. The CAJ is desirable in both sets of guidelines.¹³⁻¹⁵ Because we believe that complications associated with PICC insertion decrease when the catheter tip approaches the CAJ, we chose the stricter definition from the North American guidelines specifying the CAJ and low SVC. Our malposition rate was 16.2% (18/111) according to the North American guidelines. A previous retrospective study of PICC insertion with the Sherlock 3CG[®] TCS in ICU patients yielded a malposition rate of 56.1%, which was lower than that with the blind method.¹¹ The authors of that study defined

an adequate tip position as the low SVC and CAJ. There is no consensus regarding the landmarks of the CAJ on a chest radiograph, and our department adopted the position at 2.4 VBUs below the carina as the most reliable.¹² Although there is a difference in the definition of CAJ when read from a chest radiograph, our results suggest that the Sherlock 3CG[®] TCS reduces the number of cases of malpositioning among normally hospitalized patients compared with ICU patients. One review showed that the malposition rate ranged from 0% to 4% in normally hospitalized patients using the Sherlock 3CG[®] TCS.¹⁶ However, neither the CAJ on the chest radiograph nor an adequate catheter tip position was clearly defined in that report. Given the diversity of definitions used in comparisons of the malposition rate, the adequate catheter tip position and the position at the CAJ on a chest radiograph should be clarified.^{17,18} We believe that the present study is valuable in terms of clarifying the precise definition of the adequate position and the CAJ on chest radiographs.

We repositioned 4 catheter tips among our 18 cases of malposition. These four cases were defined as malposition according to the European guidelines. The rate of replacement of malpositioned PICCs using the Sherlock 3CG[®] TCS has not yet been reported.¹⁶ Because this replacement rate might reflect the usefulness of the Sherlock 3CG[®] TCS, further analysis is warranted. Although there is disagreement concerning the necessity of confirmation via a routine chest radiograph, we believe that such confirmation is necessary because we encountered some cases requiring replacement.

Our mean procedure length was 23.59 ± 6.56 minutes. A previous retrospective study of 60 blind insertions and 60 insertions using the Sherlock 3CG[®] TCS yielded a mean procedure time of 29.05 ± 7.84 and 33.93 ± 25.63 minutes, respectively.³ These times did not include the time required for

placement confirmation or repositioning. Our data included the confirmation time; however, the procedure length was shorter than that in previous reports. Although comparison of the procedure duration between previous studies of blind insertion and the present study, our procedure time is thought to be acceptable.

In the present study, we found no significant difference in the malposition rate between the sexes. However, the malposition rate was higher in female patients than in male patients. We defined the CAJ as a point 2.4 VBUs below the carina in accordance with previous studies. Our study showed that the distance from the carina to the CAJ (in VBUs) was greater in older female patients, presumably because of the reduction in the vertebral body height caused by osteoporosis.¹² Our malposition cases may have also been influenced by this factor.

Similarly, we found no significant difference in the puncture side. Generally, PICC insertion in the left arm requires more experience because the distance from the puncture point to the CAJ is longer than that from the right arm. A previous study showed that the malposition rate was lower in right- than left-sided catheters with blind insertion.⁴ Further malposition analysis with the Sherlock 3CG[®] TCS remains to be performed in a larger patient population.

This study also showed no significant difference in the operator's experience level. This result implies that catheter tip positioning with the magnetic sensor and IC-ECG does not necessarily require extensive experience. The success rates for relatively inexperienced radiologists in this study were close to those of general practitioners whose specialty was not radiology, and these general practitioners were able to easily insert bedside PICCs using the Sherlock 3CG[®] TCS.

This study had several limitations. Bias cannot be ruled out because of the single-center, single-arm study design, and all procedures were conducted by a radiologist in one interventional radiology room. Further research is needed to fully evaluate cases of replacement and additional procedure time, and better landmarks of the CAJ on chest radiographs should be sought.

In conclusion, PICC placement using the Sherlock 3CG[®] TCS for normally hospitalized patients demonstrated a high technical success rate and a low catheter tip malposition rate. Our results also suggest that this technique is useful regardless of the radiologist's level of experience and side of insertion. These results indicate that PICC insertion with the Sherlock 3CG[®] TCS is a feasible and safe method.

Declaration of conflicting interest

The authors declare that there is no conflict of interest.

Funding

This research received no specific grant from any funding agency in the public, commercial, or not-for-profit sectors.

ORCID iD

Tomomi Yamagishi  <http://orcid.org/0000-0003-0629-2932>

References

1. Johnston AJ, Bishop SM, Martin L, et al. Defining peripherally inserted central catheter tip position and an evaluation of insertions in one unit. *Anaesthesia* 2013; 68: 484–491.
2. Yuan L, Li R, Meng A, et al. Superior success rate of intracavitary electrocardiogram guidance for peripherally inserted central catheter placement in patients with cancer: a randomized open-label controlled multi-center study. *PLOS One* 2017; 12: e0171630.

3. Tomaszewski KJ, Ferko N, Hollman SS, et al. Time and resources of peripherally inserted central catheter insertion procedures: a comparison between blind insertion/chest X-ray and a real time tip navigation and confirmation system. *Clinicoecon Outcomes Res* 2017; 9: 115–125.
4. Venkatesan T, Sen N, Korula PJ, et al. Blind placements of peripherally inserted antecubital central catheters: initial catheter tip position in relation to carina. *Br J Anaesth* 2007; 98: 83–88.
5. Glauser F, Breault S, Rigamonti F, et al. Tip malposition of peripherally inserted central catheters: a prospective randomized controlled trial to compare bedside insertion to fluoroscopically guided placement. *Eur Radiol* 2017; 27: 2843–2849.
6. McGee DC and Gould MK. Preventing complications of central venous catheterization. *New Engl J Med* 2003; 348: 1123–1133.
7. Elsharkawy H, Lewis BS, Steiger E, et al. Post placement positional atrial fibrillation and peripherally inserted central catheters. *Minerva Anestesiol* 2009; 75: 471–474.
8. Orme RML, McSwiney MM and Chamberlain-Webber RFO. Fatal cardiac tamponade as a result of a peripherally inserted central venous catheter: a case report and review of the literature. *Br J Anaesth* 2007; 99: 384–388.
9. Verso M, Agnelli G, Kaphuisen P, et al. Risk factors for upper limb deep vein thrombosis associated with the use of central vein catheter in cancer patients. *Intern Emerg Med* 2008; 3: 117–122.
10. Amerasekera SSH, Jones CM, Patel R, et al. Imaging of the complications of peripherally inserted central venous catheters. *Clin Radiol* 2009; 64: 832–840.
11. Johnston AJ, Holder A, Bishop SM, et al. Evaluation of the Sherlock 3CG Tip Confirmation System on peripherally inserted central catheter malposition rates. *Anaesthesia* 2014; 69: 1322–1330.
12. Song YG, Byun JH, Hwang SY, et al. Use of vertebral body units to locate the cavoatrial junction for optimum central venous catheter tip positioning. *Br J Anaesth* 2015; 115: 252–257.
13. Vesely TM. Central venous catheter tip position: a continuing controversy. *J Vasc Interv Radiol* 2003; 14: 527–534.
14. Bishop L, Dougherty L, Bodenham A, et al. Guidelines on the insertion and management of central venous access devices in adults. *Int J Lab Hematol* 2007; 29: 261–278.
15. Funaki B. Central venous access: a primer for the diagnostic radiologist. *AJR Am J Roentgenol* 2002; 179: 309–318.
16. Dale M, Higgins A, and Carolan-Rees G. Sherlock 3CG[®] tip confirmation system for placement of peripherally inserted central catheters: a NICE medical technology guidance. *Appl Health Econ Health Policy* 2016; 14: 41–49.
17. Ridge CA, Litmanovich D, Molinari F, et al. Radiographic evaluation of central venous catheter position: anatomic correlation using gated coronary computed tomographic angiography. *J Thorac Imaging* 2013; 28: 129–133.
18. Aslamy Z, Dewald CL, Heffner JE. MRI of central venous anatomy: implications for central venous catheter insertion. *Chest* 1998; 114: 820–826.